

Effects of Cimetidine and Bromocriptine on Germinal Epithelium and Spermatogenesis

Qamar Hamid, Sadaf Hamid, Liaqat Ali Minhas, Anjuman Gul

Abstract— The present study was designed to see the influence of parenterally administered drugs cimetidine and bromocriptine on the germinal epithelium of adult male albino rats and its relation with spermatogenesis. Ninety adult young male albino rats between the ages of 60 to 120 days were selected. The animals were divided into three groups. Cimetidine was administered in a dose of 200 mg/kg body weight to group B intramuscularly and in addition to cimetidine, bromocriptine in a dose of 2.5 mg/day intramuscularly was given to group C. Normal saline was administered intramuscularly to control group A. Spermatogonia, spermatocytes, and spermatids were studied under oil immersion. The spermatogenesis was normal in almost all of the tubules of group B but a few of them were seen lined with only Sertoli cells and all the other germ cells like spermatogonia, primary spermatocytes, spermatids early and late, and spermatozoa were absent indicating total atrophy with both Sertoli cells and Leydig cells hyperplasia. However, the seminiferous tubules of group C were showing disorganisation/disruption or both at the level of basal compartment of germinal epithelium in small quadrants, a quarter, half or more than half of their tubules indicating partial atrophy. Both normal and abnormal germinal epithelium was seen in same/different tubules but a few of them were seen lined with only Sertoli cells and all the other germ cells like spermatogonia, primary spermatocytes, spermatids early and late, and spermatozoa were absent. On the basis of the results of present study we could not exclude the possibility that besides the known anti-androgenic effect of cimetidine, a possible interference of cimetidine on the histoarchitecture of the seminiferous epithelium, as well as lack of other biochemical factors essential for spermatogenesis could be involved in the testicular changes/ alterations of both groups B and C.

Index Terms— spermatogenesis, cimetidine, bromocriptine.

I. INTRODUCTION

Cimetidine (Tagamet) has been widely prescribed for about 20 years worldwide. It is a potent histaminic H₂-receptor antagonist¹, extensively prescribed for ulcers and now available without prescription. The major therapeutic indications for cimetidine are for promoting healing of gastric and duodenal ulcers and for prophylaxis of stress ulcers. Cimetidine can be administered intravenously for acute gastrointestinal disorders or can be taken orally for

chronic gastrointestinal problems. Cimetidine is also known reproductive toxicant as indicated by significantly reduced weight of accessory sex organs². It is also responsible for sexual dysfunction³ such as impotence⁴ oligospermia, decrease in sexual drive & desire as well as erection and it can also cause gynaecomastia in males and pain and tenderness in breasts as well as galactorrhea⁵ in females. A decrease in testicular weight is also reported in rats treated with a high dose⁶ of 950 mg/kg/day. The reduction in testicular size is also supported by other statistically significant parameters determined by morphometry. Reductions in sperm count have been reported in men. These effects are mainly seen with long-term use of cimetidine in high doses. The data suggest that more studies in the human are necessary to determine if adverse cimetidine-related reproductive consequences may occur. After a thorough review of recent literature regarding the possible side effects of cimetidine, this study was planned to establish the factor/factors responsible for the alteration in the structure of the testis

II. RESEARCH DESIGN AND METHODS

This study was conducted at the Department of Anatomy, Army Medical College (AMC), Rawalpindi in collaboration with National Veterinary Laboratories (NVL), ChakShahzad, Islamabad. Ninety adult young male albino rats between the ages of 60 to 120 days were selected. They were bred in the animal house of the National Institute of Health (NIH), Islamabad and were supplied with diet pellets supplemented with vitamins and water ad libitum. The animals were divided into following three groups:-

A. Group A

Thirty male rats were given injection of one ml of normal saline intra- muscularly daily for two weeks and killed on the next day after the last injection. This group served as control for group “B” and “C”.

B. Group B

Thirty male rats were given the injection of cimetidine intramuscularly in a dose of 200 mg/kg body weight daily for two weeks and killed on the next day after the last injection .

C. Group C

Thirty male rats were given injection of cimetidine intramuscularly daily in a dose of 200 mg/kg and in addition an injection of bromocriptine 2.5 mg was also given intramuscularly to each animal of this group for two weeks

Qamar Hamid Department of Anatomy, Shaheed Benazir Bhutto medical college Lyari, Karachi

Sadaf Hamid Department of Anatomy, Sindh Medical College(JSMU), Karachi-755100, Pakistan

Liaqat Ali Minhas Department of Anatomy, Army Medical College, Rawalpindi, Pakistan

Dr. Anjuman Gul, 4Department of Biochemistry, Qaseem University Buraida, Saudi Arabia

and were killed on the next day after the last injection .

The scrotal sac was opened with the help of forceps and scissors. Testes were removed, weighed and then put into 10% formalin for fixation. They were rinsed with 70% alcohol and kept in it over night. Next day the tissues passed through ascending series of alcohol from 70% to 100% cleared in xylene, infiltrated and embedded in paraffin wax at 58°C. Five micron thick sections were cut on rotatory microtome, floated on warm water bath at 45°C, and then mounted on glass slides, fixed on hard hot plate at 37°C for twenty four hours. The section were then stained with Periodic acid schiff (PAS) reagent⁷ and counter stained with Harris's haematoxylin and also with routine Haematoxylin&Eosin(H&E) stain.

III. OBSERVATIONS:

The height of germinal epithelium was measured (in micrometers under high power field) with a ocular micrometer.

Germ Cells Study:--spermatogonia, spermatocytes, and spermatids were studied under oil immersion. Stages of spermatogonia were designated accordingly to Leblond and Chermont. Morphological changes in the cells such as necrosis, degeneration etc. were noted. Presence or absence of abnormal cells such as multinucleated giant cells was also observed.

IV. STATISTICAL ANALYSIS OF THE DATA

The statistical significance of the difference of various quantitative changes between the experimental and control groups was evaluated by "Student" "t" test¹⁰ The difference was regarded statistically significant if the "P" value was equal to or less than 0.05.

V. RESULTS

The present study was carried out to see the role of drugs upon the germinal epithelium of the gonads of male rats and the process of spermatogenesis.

GROUP 'A':

Initially we started with thirty rats but since ten of them died on the very same date due to change of place and bad weather conditions prevailing in our laboratory as there was some fault in the cooling system. Therefore we were forced to proceed with only twenty animals as controls in the present study as compared to thirty animals in both experimental groups B and C and also since ten extra adult male rats of the same strain were not available at the present centre.

VI. QUANTITATIVE FINDINGS OF GROUP A (CONTROL):

The mean thickness of germinal epithelium was 66.53 ± 1.841 micrometers.

A. Qualitative Findings of Group A (Control)

Disruption/vacuolisation of germinal epithelium was not noted. The process of spermatogenesis proceeded normally.

The seminiferous tubules did not show any disruption of the basement membrane/germinal epithelium/both. The basement membrane was not found discontinuous/thickened. The process of spermiogenesis proceeded normally as indicated by tails of sperms and residual bodies (Fig.1). Pyknosis, karyorrhexis, karyolysis or apoptosis was not seen

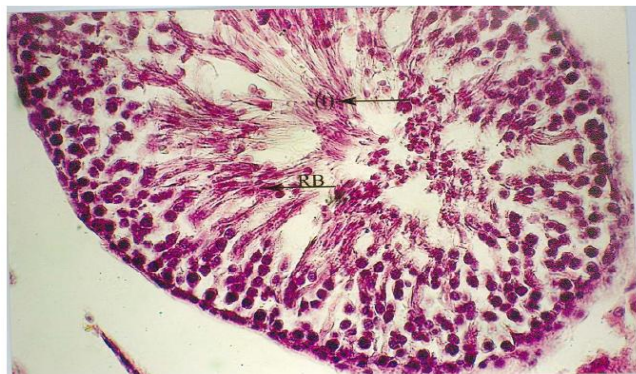

Fig.1: Section of testis Control (Group A) showing normal spermatogenesis and normal spermiogenesis indicated by tails (t) of sperms and residual bodies (RB) Haematoxylin& eosin stain. (Photomicrograph x 400)

B. Quantitative Findings Of Group B:

The mean thickness of germinal epithelium was 59.9 ± 1.354 micrometers again lower than that of control (Table 1, Fig.3) but higher than that of group C.

The difference was highly significant statistically ($P < .005$) when compared with control. The difference was not significant when compared with group C.

All tubules did not show disorganisation but a few of them displayed disruption and disorganisation of germinal epithelium or both. A few seminiferous tubules were visible with basement membrane which was disrupted/discontinuous at places, while thickened/hyalinised in atrophic tubules. The spermatogenesis was normal in almost all of the tubules but a few of them were seen lined with only Sertoli cells and all the other germ cells like spermatogonia, primary spermatocytes, spermatids early and late, and spermatozoa were absent indicating total atrophy with both Sertoli cells and Leydig cells hyperplasia. On the whole there was no mass of necrotic cells visible but in a few tubules where layers of germ cells were reduced indicating suppressed process of spermatogenesis (Fig.2), the lumen was filled with single/multiple scattered apoptotic/giant cells or at places the germinal epithelium had undergone the process of vacuolisation. In almost all the tubules the process of spermiogenesis proceeded normally.

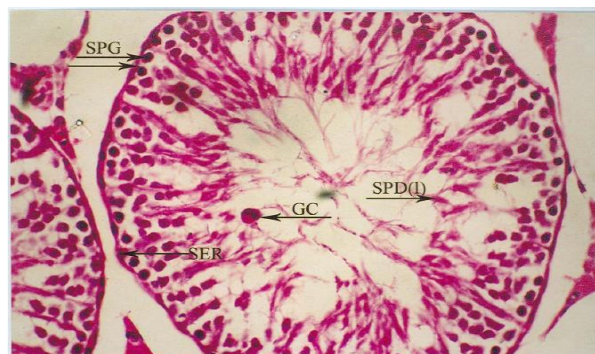


Fig. 2:Section of cimetidine treated testis, (group B), showing two tubules. Tubule on the right shows reduced number of primary spermatocytes and spermatids near lumen is a giant cell (GC), Late spermatids SPD(I). Triangular nucleus of sertoli cell (SER) near basement membrane on left.Spermatogonia (SPG) on the top left side). Haematoxylin& Eosin stain. (Photomicrograph x 400).

Table No. 1
Mean* Thickness Of Germinal Epithelium (Mm) Of Testes Of Animals Of Different Groups

GROUPS	THICKNESS OF GERMINAL EPITHELIUM (μm)
A n=30	66.53 \pm 1.841
B n=30	59.90 \pm 1.354
C n=30	59.32 \pm 1.106

* Mean \pm SEM

Statistical Analysis of The Difference in Thickness of Germinal Epithelium Within Groups

Groups	P- Value
A VS B	P < 0.005
A VS C	P < 0.04
CVS B	P > 0.7

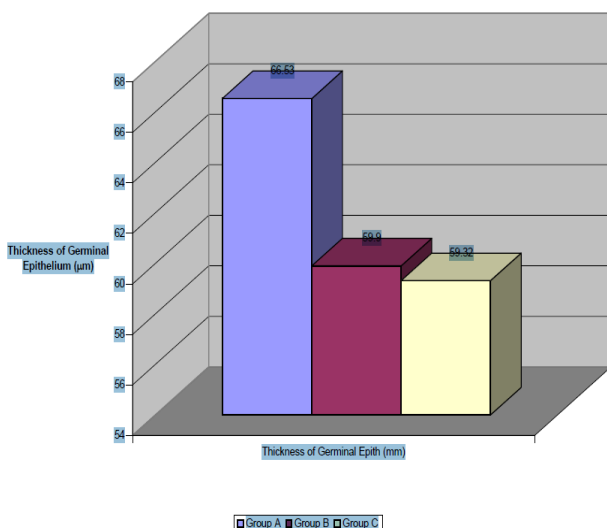


Fig. 3 Mean thickness of germinal epithelium (μm)

C. Quantitative Findings of Group C:

The mean thickness of germinal epithelium was 59.32 \pm 6.057 μm . It was lowest amongst all the three groups i.e., AB&C. It was found to be lower than both B as well as control.

The difference was found to be statistically significant (P < 0.05) (Table 1, Fig.3) when compared with control but it was not considered significant when compared with group B. Most of the seminiferous tubules were showing disorganisation/ disruption or both at the level of basal compartment of germinal epithelium in small quadrants, a quarter, half or more than half of their tubules indicating partial atrophy. Both normal and abnormal germinal epithelium was seen in same/different tubules but a few of them were seen lined with only Sertoli cells and all other germ cells like spermatogonia, primary spermatocytes, spermatids early and late, and spermatozoa were absent. All types of spermatogonia A, B & intermediate were absent at

places where extensive vacuolisation/ disruption had occurred. Even the connective tissue surrounding the tubules was sparse/absent. The interstitial tissue appeared to be normal at places while at other places displayed hyperplasia and congestion.

Apart from the above findings some of the spermatocytes displayed the stages of metaphase and anaphase of meiosis I & II. The spermatogonia, primary spermatocytes and the spermatid were visible indicating that no developmental arrest was present. There were abnormally looking cells present which were atypically located in the tubule and appeared to be undergoing the process of apoptosis.

The process of spermatogenesis was variable and appeared to be normal in most but in some it was found to be suppressed. The process of spermiogenesis was variable appeared to be normal in most but in some it was again found reduced/ suppressed. There was a focal disruption of germinal epithelium (germ cells) as well as disorganization (Fig. 4) with disruption of basement membrane/both.

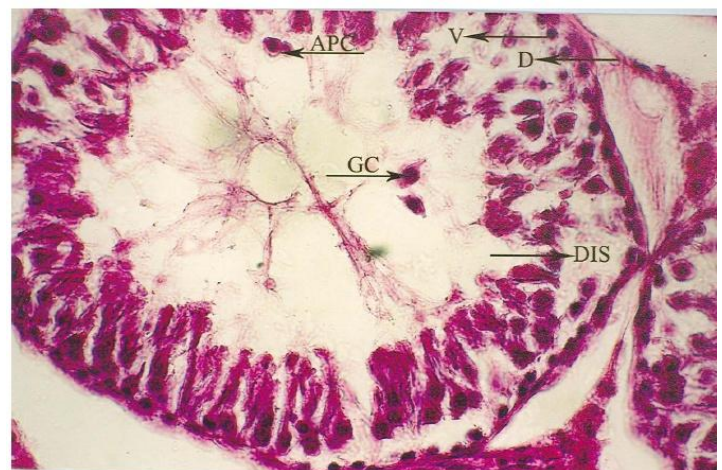


Fig. 4Section of cimetidine & bromocriptine treated testis, (GROUP C) showing giant Cell (GC) disorganization (D) disruption (DIS) Vacuolization (V) and apoptotic cells (APC) in the lumen of a seminiferous tubule. Haematoxylin& eosin stain (Photomicrograph x 400)

VII. DISCUSSION

The morphometry of seminiferous tubules indicated highly significant reduction in the diameter and thickness of germinal epithelium of group B, while insignificant reduction in the diameter of group C but significant reduction in the thickness/height of germinal epithelium of group C. In addition to the above mentioned findings certain other peculiar features indicating degeneration were also seen such as hyalinization of the peripheral tubules along with Leydig cell hyperplasia which is partly in agreement with a recent study¹¹ where “Higher statically significant incidence of benign Leydig cell tumours in cimetidine treated groups as compared to control” has been reported. Multinucleated giant cells were seen either singly or in groups near the lumen showing to have engulfed some structures derived from the acrosomic system indicating some degeneration or necrotic process to be going on which is partly in agreement with another study¹² which has reported about multinucleated giant spermatid in their study. Number of Apoptotic cells,

most probably the pachytene primary spermatocyte/spermatid/spermatogonia, signaling the impending death of germ cells¹³. A recent study¹¹ has reported lack of contact between sertoli cells and spermatids in tubules at stage IX, suggesting a possible interference of cimetidine on the histoarchitecture of the seminiferous epithelium. These data strongly support the notion that prolactin acts directly at the testicular level and acts synergistically with gonadotrophins to regulate long term cycles in testicular activity in seasonally breeding mammals such as the red deer and sheep¹⁴⁻¹⁷ Since both drugs cimetidine as well as bromocriptine have been given in case of group C18 since cimetidine elevates serum prolactin which is blocked/neutralized by bromocriptine which reduces serum prolactin, thus does not allow cimetidine to affect the gonads adversely, by preventing hypogonadism, which in male rats, indicate sexual dysfunction and loss of libido, by a direct stimulatory effect on follicle stimulating hormone, leading to increase in the weight/ size of the testes. On the basis of the results of group C it is proposed that since both drugs cimetidine as well as bromocriptine have acted synergistically/agonistically to raise the level of serum prolactin though insignificant which is not blocked by a meager 2.5mg/day dose of bromocriptine. So the adverse effect on the height of germinal epithelium as well as qualitative testicular changes could be due to:

1. A low dose of bromocriptine
2. different species/strain of rat
3. resistance of the drug (bromocriptine) itself
4. ineffective/tolerant brand of bromocriptine
5. shorter duration of study or
6. Increased production of stress

VIII. CONCLUSION

On the basis of the results of present experiment it is concluded that the testicular atrophy as evidenced by decrease in diameter of tubules in case of group B and adverse effects on the qualitative changes such as cellular proliferation/spermatogenesis as well as quantitative morphometric parameters such as decrease in thickness of germinal epithelium in case of both group B as well as C could be due to the toxic effect of the drugs on the testes in general and seminiferous tubule in particular. In the present study it has not been shown to be mediated through hormones which needs further research work. Due to the limitations of the present experimental set up the role of prolactin in causing testicular atrophy after cimetidine administration could not be determined. So it is suggested that further research work using similar species of rats with a low dose and longer duration might be required to elaborate the factor/factors responsible for affecting the gonads.

REFERENCES

- [1] Parson ME. The antagonism of histamine H₂ receptors in vitro and in vivo with particular reference to the action of cimetidine. In: Creutzfeldh W. editor Cemetidine: Proceedings of an international symposium on Histamine H-2 Receptor Antagonists. Amsterdam – Oxford: Excerpta Medica;1977.p.13-20.
- [2] France LR, Leal MC, Sasso-Cerri E, Vaconcelos A, Debeljuk L, Russell LD. Cimetidine is reproductive toxicant in male rats affecting peritubular cells. *Biology of reproduction* 2000; 63:1403-12.

- [3] Galbraith RA, and Michnovicz JJ. The Effects of cimetidine on the oxidative metabolism of estradiol. *NEJM*. August3, 1989;321(5)269-74.
- [4] Schroeder K. Sex Rx: cimetidine and your sex life. *Al-Hikmah Health Education*[al-hikmah.org]. 2005 [2001 Oct]; Available from: <http://www.al-hikmah.org/sex-rx-cimetidine-and-your-sex-life.htm>.
- [5] Sharpe PC, Hawkins B W Efficacy and safety of cimetidine. Long term treatment with cimetidine. In: Burland WL, Simkins MA, editors. *Cimetidine; Proceedings of the second International Symposium on histamine H₂ – receptor antagonists*. Amsterdam-Oxford: ExcerptaMedica; 1977.p.358-70.
- [6] Qamar H, Khan MY. Study of the effects of Cimetidine upon rat testes. *Pak Armed ForcesMedJ*.2005;55(2):106-10
- [7] Bancroft JD, Stevens A. *Theory and practice of histological techniques*. 1sted. Edinburgh and New York: Churchill Livingstone; 1977.
- [8] Humason GL. *Animal Tissue techniques: 2nded*. San Fransisco; WH Freeman; 1967.
- [9] Leblond CPC, Clermont Y. Definition of stages of the cycle of seminiferous epithelium in the rat. *Ann N.Y Acad Sc*.1952;55:548-73.
- [10] Glaser AN. *High yield biostatistics*: Philadelphia: Lippincott. Williams & Wilkins; 2001.p.28-30.
- [11] ErfanEilati: A review of cimetidine (tagamet) effects as a reproductive toxicant in male rats Leydig cells. *Endocrine Abstracts*. Bio Scientifica. 2006;697.
- [12] Sasso-Cerri E, Glovanoni M, Hayashi H, I Miragila, SM Morphological alterations and intratubular lipid inclusions as indicative of spermatogenic damage in cimetidine treated rats. *Archives of Andrology*.Jan 2001;46;(9):5-13.
- [13] Nagata S Apoptosis by death factor. *Cell*. 19976, 88:355-65.
- [14] Sanford LM Dickson KA. Seasonality in reproductive processes in rams with suppressed prolactin secretion. *Fertility and Sterility*.1980;34:192-3.
- [15] Howles CM, Craigon J Haynes NB. Long-term rhythms in testicular volume and plasma prolactin concentrations in rams reared for 3 years in constant photoperiod. *Journal of Reproduction and Fertility*.1982;65:439-46.
- [16] Sanford LM, Howland BE Palmer WM. Seasonal changes in the endocrine responsiveness of the pituitary and testes of male sheep in relation to their patterns of gonadotrophic hormone and testosterone secretion. *Canadian Journal of Physiology and Pharmacology*.1984a;62:827-33.
- [17] Sanford LM, Howland BE, Palmer WM. Seasonal changes in the secretion of gonadotrophic hormones and in the endocrine response of the pituitary of male sheep in the absence of gonadal influence. *Canadian Journal of Physiology and Pharmacology* 1984b;62:834-9.
- [18] Kikuyama S, Yamamoto K Prolactin and amphibian metamorphosis. In: Hoshino K editor *Prolactin: Gene family and its receptors*. Amsterdam: Elsevier Science Publishers B.V; 1988.P.359-66.